

## INVESTIGATIVE REPORT

# Important Factors for Pain during Photodynamic Therapy for Actinic Keratosis

Carin SANDBERG<sup>1</sup>, Bo STENQUIST<sup>1</sup>, Inger ROSDAHL<sup>2</sup>, Anne-Marie ROS<sup>3</sup>, Ingrid SYNNERSTAD<sup>2</sup>, Maria KARLSSON<sup>3</sup>, Fredrik GUDMUNDSON<sup>4</sup>, Marica B. ERICSON<sup>1</sup>, Olle LARKÖ<sup>1</sup> and Ann-Marie WENNERBERG<sup>1</sup>

Department of Dermatology, <sup>1</sup>Sahlgrenska University Hospital, Göteborg, <sup>2</sup>Linköping University Hospital, Linköping, <sup>3</sup>Karolinska University Hospital, Stockholm, and <sup>4</sup>Chalmers University of Technology, Göteborg, Sweden

**Photodynamic therapy (PDT) is an efficient treatment for actinic keratosis. A common problem, however, is pain. The aim of this study was to investigate pain during PDT for actinic keratosis. The possibility of using capsaicin cream for pain relief was also assessed. Pain was investigated during aminolaevulinic acid PDT in 91 patients. Size, redness, scaling and induration of the lesions were recorded. Maximum pain during treatment was registered, using a visual analogue scale (0–10). The pain-reducing efficacy of capsaicin was tested in a pilot study in six patients (10 lesions). These patients were pre-treated with capsaicin cream for one week before commencing PDT. Pain was found to be normally distributed around a mean value of visual analogue scale 4.6. Larger lesions gave more pain ( $p=0.001$ ). The redness of the actinic lesions was found to be related to PDT-induced pain ( $p=0.01$ ), the reduction of actinic area ( $p=0.007$ ), and the cure rate ( $p=0.01$ ). The redder the actinic area, the better the treatment outcome and the more pain experienced. Patients with the largest reduction in the actinic area experienced more pain ( $p=0.053$ ). The most important factors for presence of pain seem to be the size and the redness of the lesion. No significant pain relief was experienced after pre-treatment with capsaicin. Key words: actinic keratosis; aminolaevulinic acid; capsaicin; pain; PDT.**

Carin Sandberg, Department of Dermatology, Sahlgrenska University Hospital, SE-413 45 Göteborg, Sweden. E-mail: carin.sandberg@vgregion.se

(Accepted March 31, 2006.)

Acta Derm Venereol 2006; 86: 404–408.

Photodynamic therapy (PDT) is now an established method to treat superficial basal cell carcinoma (SBCC), Bowen's disease (BD) and actinic keratosis (AK) (1–5). There is no difference in the cure rate of superficial skin lesions between PDT and excisional surgery, curettage-electrodesiccation or cryotherapy (1, 3, 6–8). The main advantage of PDT is that the method is non-invasive and generally leads to excellent cosmetic results. Hence PDT is an attractive treatment modality. The majority of the patients experience some degree of stinging, burning or pain during PDT (5). We have previously shown that the

peak of pain is reached after a few minutes of irradiation, and then gradually decreases towards the end of the treatment period (9), which verifies observations by Kennedy & Pottier (10). In another previous study from some of the present authors, it was demonstrated that patients with AK seem to suffer from more intense pain than those with BD or SBCC (5). Furthermore, it was shown that PDT of larger lesions and lesions localized on the scalp and forehead was associated with more pain than that of lesions on other sites (5, 11).

The mechanism behind the PDT-induced pain is as yet unknown. Local hyperthermia and cytotoxic oxygen have been suggested to contribute (12, 13). One hypothesis proposed is that aminolaevulinic acid (ALA) is actively transported into the peripheral nerve-endings, triggering nerve stimulation when illuminated (11, 14). Following PDT and cell necrosis, inflammation is generated which might add to the stinging and discomfort later in the process (13).

Pain is generally believed to be mediated through the unmyelinated afferent c-fibres, and involves substance P and other neurotransmitters. The pain experienced by the patients during PDT has been found to be difficult to treat (5). Cold air, cooling fans and spraying of water are routinely used, but have limited effect (2, 3, 5–7, 15, 16). Topical tetracaine was investigated recently but did not differ from placebo (17). Lidocaine-cream (EMLA<sup>®</sup>, Astra/Zeneca, Södertälje, Sweden) and infiltration of local anaesthetics have been tried with limited success (1, 3, 5).

Repeated contact with capsaicin, a chilli-pepper, is thought to deplete substance P and other transmitters from the nerve-endings and produce desensitization (18, 19). In a large review of pooled data it was found that capsaicin was effective in reducing chronic pain from neuropathy and muscular-skeletal disorders (20).

The aim of this study was to investigate which factors are related to pain during PDT for AK. In addition, the possibility of reducing the pain by pre-treatment of the lesion with capsaicin cream was investigated in a pilot study.

## PATIENTS AND METHODS

### Patients

The patients were recruited at 10 centres. The local Ethics Committee of Linköping approved the study. In total, 94 patients

(70 men and 24 women), aged 52–91 years (mean 76 years), with AK on the head or upper chest region entered the study. The inclusion criterion was either one clinically diagnosed AK measuring  $> 2$  cm in diameter or at least two AKs within an area of  $5 \times 5$  cm. The AK lesions were classified in 5 different size categories, 1–5%, 6–25%, 26–50%, 51–75% and 76–100% of the area treated. In addition the lesions were rated according to redness, scaling and induration (mild, moderate and severe). The pain during treatment was recorded by using a visual analogue scale (VAS), as described below. All lesions were biopsied and only histologically verified AKs were included in the analyses. Three patients were excluded, two because they histologically showed BD and a third due to technical problems during the treatment. Thus 91 patients remained for evaluation. All patients were classified according to skin type and the cure rate after PDT was registered after 6–8 weeks.

To test the possible pain-reducing effect of capsaicin, an additional group of 7 patients (5 men and 2 women), aged 50–81 years (mean 65 years), were included in a pilot study carried out at the Department of Dermatology at Sahlgrenska University Hospital, Göteborg, Sweden. We compared the experienced pain with and without pre-treatment with capsaicin before PDT, using the same light and the same preparation before PDT, with the same location and lesion type. The inclusion criterion was that a previous PDT had caused severe pain (VAS 7–10). The local Ethics Committee approved the study. One patient discontinued the study due to local side-effects. In the remaining 6 patients, 10 lesions were studied: 8 AKs, 1 SBCC and 1 BD, all histologically verified.

#### Photodynamic treatment

The ALA cream (Porphin cream, Crawford Pharmaceuticals Ltd, Milton Keynes, UK), consisting of 20% w/w 5-ALA-HCl in Unguentum-Merck® (Darmstadt, Germany) was applied under occlusion for 3 h in a  $5 \times 5$  cm chamber made of DuoDERM (ConvaTec, Bromma, Sweden) with 1 mm depth. We used a non-coherent spectrally shifted sodium lamp (Photodermation System 1, Prototype 5 Medekon AB, Göteborg, Sweden). The light from the lamp was filtered with a long-pass filter so that the emission spectrum (590–650 nm) matched the absorption peak of the photosensitizer PpIX at approximately 635 nm. The fluence rate was  $70 \text{ mW/cm}^2$  and the dose was  $70 \text{ J/cm}^2$ . Complete response was defined as clinically 0–1% remaining AK.

In the capsaicin study, we used ALA-cream prepared at the local hospital pharmacy, consisting of 20% w/w 5-ALA HCl (Medac, Hamburg, Germany) in an ointment base (Unguentum-Merck®). Here a PDT 1200 lamp (Waldmann Medical, Schwenningen, Germany) with a wavelength interval of 600–730 nm was used, in order to use the same light source as during the earlier treatment of these patients. The patient applied capsaicin-cream on the treatment area 3–5 times per day for one week before treatment. The capsaicin-cream used was Capsina® (AstraZeneca, Södertälje, Sweden) consisting of 0.075% capsaicin, registered for post-herpetic neuralgia.

#### Pain registration

Pain registration was performed using a VAS, graded from 0 (no pain) up to 10 (unbearable pain). Low pain or no pain was defined as VAS 0–3, moderate pain as VAS 4–6 and severe pain as VAS 7–10. Before treatment, the scale was explained to the patients. Immediately after PDT the patients were asked to record their maximum pain on the scale. The environment has been standardized in all PDT-sessions. A nurse was always present for supervision. Fans and cold water-spraying were used when needed. All patients were offered short breaks from illumination if necessary. No analgesics or anaesthesia were given.

#### Statistics

Independent *t*-test procedure was used to examine differences between two groups. When comparing more than two groups, analysis of variance (ANOVA) and analysis of covariance (ANCOVA) were used. A Jarque Bera test using Matlab® Statistics Toolbox was applied to analyse population distribution.

## RESULTS

During PDT we found a large variation in level of pain experienced by the patients (Fig. 1). The pain score was normally distributed ( $p=0.34$ ) around a mean value of VAS 4.6. Twenty-one percent of the patients ( $n=19$ ) had severe pain (VAS 7–10) and 31% of the patients ( $n=29$ ) had no pain at all or low pain (VAS 0–3). The AK area was expressed as percentage of the  $25\text{-cm}^2$  area treated. The AK lesions were divided into five different size categories (Fig. 2). The patients with larger involved areas (51–100%) were found to experience significantly more pain than those with smaller areas (1–50%,  $p=0.001$ ).

The redness of the AK lesions was also found to be significantly related to pain ( $p=0.01$ ), the reduction in AK area ( $p=0.007$ ), and the cure rate ( $p=0.01$ ). Mild redness differed from moderate redness ( $p=0.001$ ). Severe redness had an even higher mean VAS, but no significance was found in that group due to the small number of patients ( $n=7$ ). The redder the AK, the better the treatment outcome and the more pain experienced. In addition, the redness was found to correlate with the size of the lesion ( $p=0.0004$ ).

Patients with the largest reduction in AK area seemed to experience more pain ( $p=0.053$ ). A tendency for more pain in the patients with the skin type I–III ( $n=88$ ) compared with those with skin-type IV ( $n=3$ ) was found although statistical significance was not reached ( $p=0.058$ ). There was no significant difference between men ( $n=69$ ) and women ( $n=22$ ), nor any significant difference between ages regarding pain. The cure rate showed that 77% of the patients ( $n=61$ ) were completely cured after one treatment, and 85% after two treatments (Fig. 3).

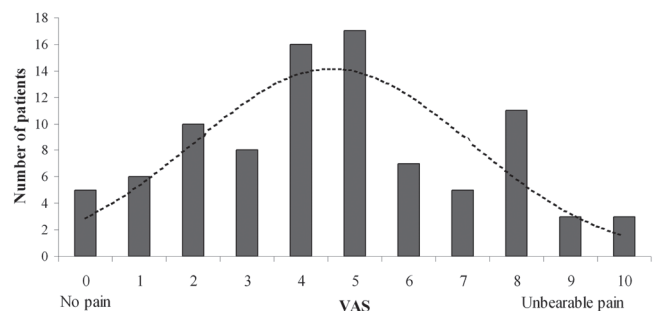


Fig. 1. Distribution of the maximum pain during photodynamic therapy, recorded by a visual analogue scale (VAS) immediately after treatment ( $n=91$  patients). The dotted line illustrates the fitted normal distribution function.

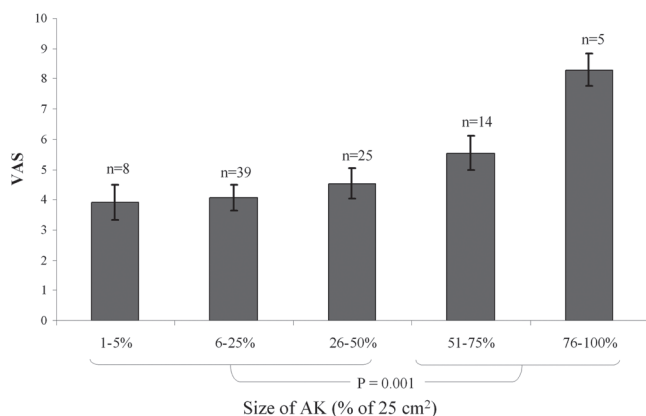


Fig. 2. Maximum pain (mean VAS +/- SEM) during photodynamic therapy for the different size groups of actinic keratosis (AK), measured as percentage of the 25 cm<sup>2</sup> area treated (*n*=number of patients).

In the pilot study of pre-treatment with capsaicin, there was no significant pain relief compared with previous treatments. All patients suffered from adverse events with erythematic skin and a burning sensation in the treatment area after applying the capsaicin cream. All adverse events subsided at the end of the pre-treatment period.

## DISCUSSION

One important factor for pain experienced by patients during PDT in this study was that treatment of larger lesions was more painful than that of smaller lesions. This is supported by earlier findings by Grapengiesser et al. (5). In addition, the redness of the AK seems to be important, since patients with intense redness experienced more pain, reduced the largest AK area and had a better cure rate. The redness is almost certainly explained by vasodilatation and the degree of inflammation; the nerve endings will probably be more sensitive. More oxygen will be available in the vasodilated area, though what effect this has is as yet unclear. The vasodilatation may lead to better penetration of the pro-drugs to the photosensitizer, leading to

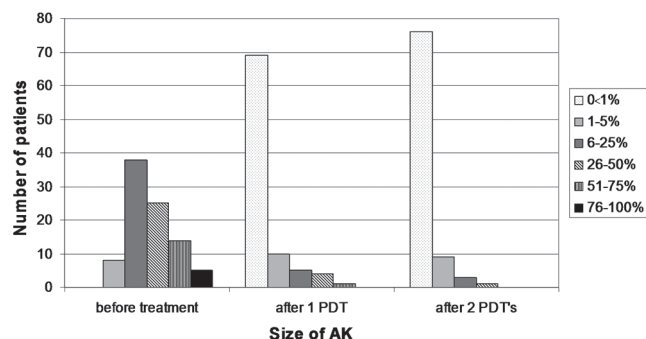


Fig. 3. Patients divided into 6 different size groups of the actinic keratosis (AK), as percentage of the 25 cm<sup>2</sup> area treated, before photodynamic therapy (PDT) and after one and two treatments, respectively.

a better cure rate. The PDT cure rate was comparable with that seen in several other studies (6, 8). We found that 77% of the patients were completely cured after one treatment and 85% after two treatments.

In our trial with high-output broadband exposure, we found that 21% of the patients experienced severe pain (VAS 7–10) and 31% noted no or slight pain (VAS 0–3), using red light (wavelength 635 nm) and ALA. Our results are similar to those of Grapengiesser et al. (5), in whose study there was a mixed material of skin tumours: BCC, AK and BD. In both our study and Grapengiesser's investigations approximately 20% of the patients (exposed to a high-output broadband light source) reported severe pain. This is further supported by Clark et al. (21). They used a non-coherent light-source (Waldmann 1200) with differentiated doses of 50–130 J/cm<sup>2</sup> ALA-PDT of BD, SBCC and AK, and demonstrated that severe pain was experienced in 16–21% of the patients treated with high-output broadband and laser (80–150 mW/cm<sup>2</sup>), but only 2% with the low-output broadband (20–25 mW/cm<sup>2</sup>). An alternative treatment would be to use low-output broadband to reduce the pain. In addition, as shown by Ericson et al. (9), low fluence rate is preferable for treatment outcome.

Green light has been proposed to be less painful by Fritsch et al. (22). They showed that green light was less painful than red light in the treatment of AKs. Morton et al. (23) compared the effects of red and green light in the treatment of BD and found that green light was less effective than red light, probably because green light does not penetrate more than 1–2 mm of the skin compared with 5–6 mm for red light, while the frequency and severity of the pain were similar between the treatment groups.

In this study we have also found that treating larger lesions resulted in more pain, which is supported by our previous study on smaller groups of patients and a mixture of tumours (5). Those who reduced their area of AK most had more pain. Ericson et al. (9) have recently shown that the pain is more pronounced at the beginning of the treatment when the rate of photo-bleaching is high. Hence, the pain seems to be related to the photodynamic activity. These results verify the "no pain – no gain"-theory proposed by Morton (1).

The pain-relieving effect of one week's pre-treatment with capsaicin cream before PDT, was investigated in a pilot study. Previous results indicate that this period should be enough to cause desensitization. Wallengren and Håkanson (18) used topical capsaicin 0.1% twice daily for 3 days and made the skin unresponsive to substance P and desensitized. Nolano et al. (19) showed a significant degeneration of epidermal nerve fibres within a few days when using capsaicin 0.075%. There are other studies where the pain-reducing effect for post-herpetic pain could be expected after 2 weeks, but the concentration used was lower than in our study, only 0.025% (24–26). Mason et al. (20) have found that higher



concentration (0.075%) had a better effect on pain than lower concentration (0.025%). Here, we found no pain relief using one week's pre-treatment with capsaicin (0.075%) before PDT. Side-effects, such as burning, stinging and itching, were observed in agreement with earlier studies (27).

In a study of PDT-induced pain (28), ALA and methyl-ester-ALA as pro-drugs to photosensitizers were compared on normal tape-stripped skin. The results showed that during illumination the topical methyl-ester-ALA gave significantly less pain than ALA-cream. About 10% of the patients treated with ALA indicated severe pain (VAS 7–10), while no patients treated with methyl-ester-ALA had severe pain. It is important to repeat this study in skin tumour patients. Pain is a limiting factor if ALA is used as a pro-drug during PDT, but the pain experienced when using the methyl-ester-ALA has not yet been thoroughly investigated (1, 5, 29). There is also a possibility that there are differences between various preparations of ALA-cream. The one we used in the studies was prepared at the university pharmacy. Another explanation for the variation in response might be that ALA is actively transported into the peripheral nerve endings, triggering nerve stimulation when illuminated, while the methyl-ester is not (11, 14).

We found that the pain experienced by patients during PDT is related to the size of the lesion. In addition, lesions with increasing redness are most painful to treat. Hence, it is of importance to find techniques for reducing discomfort in these patients without jeopardizing treatment outcome. In this study we tested pre-treatment with capsaicin cream, but no pain relief was obtained. A possibility for making the treatment more tolerable to the patient is to use fractionated doses. This has been shown to be well tolerated and at the same time to increase the cure rate (9, 30, 31). There is currently no adequate PDT protocol for the reduction of pain, but with size and redness in mind, we can identify the patients at risk for more pain and take this into consideration before giving treatment.

#### ACKNOWLEDGEMENTS

We thank the Faculty of Medicine at Sahlgrenska University Hospital, the Faculty of Health Sciences at Linköping University, and FORSS for financial support. We would also like to thank the nurses Liselotte Lundgren and Mona-Lisa Sand for their valuable help. Moreover, we would like to acknowledge Medeikonos AB, Göteborg, Sweden, for assisting with equipment and financial support. Finally, we are grateful to all participating centres for recruiting the patients.

#### REFERENCES

- Morton CA. Photodynamic therapy for nonmelanoma skin cancer – and more? *Arch Dermatol* 2004; 140: 116–120.
- Morton CA. Methyl aminolevulinic acid (Metvix) photodynamic therapy – practical pearls. *J Dermatolog Treat* 2003; 14 (suppl 3): 23–26.
- Morton CA, Brown SB, Collins S, Ibbotson S, Jenkinson H, Kurwa H, et al. Guidelines for topical photodynamic therapy: report of a workshop of the British Photodermatology Group. *Br J Dermatol* 2002; 146: 552–567.
- Szeimies RM, Karrer S, Backer H. Therapieoptionen bei epithelialen Hauttumoren Aktinische Keratosen, Morbus Bowen, spinocelluläres Karzinom und Basalzellkarzinom. *Hautarzt* 2005; 56: 430–440.
- Grapengiesser S, Ericson M, Gudmundsson F, Larkö O, Rosen A, Wennberg AM. Pain caused by photodynamic therapy of skin cancer. *Clin Exp Dermatol* 2002; 27: 493–497.
- Wang I. Photodynamic therapy and laser-based diagnostic studies of malignant tumors. PhD Thesis. Lund: Lund University, 1999.
- Chamberlain AJ, Kurwa HA. Photodynamic therapy: is it a valuable treatment option for actinic keratoses? *Am J Clin Dermatol* 2003; 4: 149–155.
- Szeimies RM, Karrer S, Radakovic-Fijan S, Tanew A, Calzavara-Pinton PG, Zane C, et al. Photodynamic therapy using topical methyl 5-aminolevulinic acid compared with cryotherapy for actinic keratosis: a prospective, randomized study. *J Am Acad Dermatol* 2002; 47: 258–262.
- Ericson MB, Sandberg C, Stenquist B, Gudmundson F, Karlsson M, Ros A-M, et al. Photodynamic therapy of actinic keratosis at varying fluence rates: assessment of photobleaching, pain and primary clinical outcome. *Br J Dermatol* 2004; 151: 1204–1212.
- Kennedy JC, Pottier RH. Endogenous protoporphyrin IX, a clinically useful photosensitizer for photodynamic therapy. *J Photochem Photobiol B* 1992; 14: 275–292.
- Brennan MJ, Cantrill RC. Delta-aminolaevulinic acid and amino acid neurotransmitters. *Mol Cell Biochem* 1981; 38: 49–58.
- Orenstein A, Kostenich G, Tsur H, Kogan L, Malik Z. Temperature monitoring during photodynamic therapy of skin tumors with topical 5-aminolevulinic acid application. *Cancer Letters* 1995; 93: 227–232.
- Gollnick SO, Evans SS, Baumann H, Owczarczak B, Maier P, Vaughan L, et al. Role of cytokines in photodynamic therapy-induced local and systemic inflammation. *Br J Cancer* 2003; 88: 1772–1779.
- Casas A, Batlle A. Rational design of 5-aminolevulinic acid derivatives aimed at improving photodynamic therapy. *Curr Med Chem Anti-Canc Agents* 2002; 2: 465–475.
- Kalka K, Merk H, Mukhtar H. Photodynamic therapy in dermatology. *J Am Acad Dermatol* 2000; 42: 389–413; quiz 414–416.
- Berg K, Anholt H, Bech O, Moan J. The influence of iron chelators on the accumulation of protoporphyrin IX in 5-aminolaevulinic acid-treated cells. *Br J Cancer* 1996; 74: 688–697.
- Holmes MV, Dawe RS, Ferguson J, Ibbotson SH. A randomized, double-blind, placebo-controlled study of the efficacy of tetracaine gel (Ametop) for pain relief during topical photodynamic therapy. *Br J Dermatol* 2004; 150: 337–340.
- Wallengren J, Håkanson R. Effects of capsaicin, bradykinin and prostaglandin E2 in the human skin. *Br J Dermatol* 1992; 126: 111–117.
- Nolano M, Simone DA, Wendelschafer-Crabb G, Johnson T, Hazen E, Kennedy WR. Topical capsaicin in humans: parallel loss of epidermal nerve fibers and pain sensation. *Pain* 1999; 81: 135–145.
- Mason L, Moore RA, Derry S, Edwards JE, McQuay HJ.

- Systematic review of topical capsaicin for the treatment of chronic pain. *BMJ* 2004; 328: 991.
21. Clark C, Bryden A, Dawe R, Moseley H, Ferguson J, Ibbotson SH. Topical 5-aminolaevulinic acid photodynamic therapy for cutaneous lesions: outcome and comparison of light sources. *Photodermatol Photoimmunol Photomed* 2003; 19: 134–141.
  22. Fritsch C, Stege H, Saalman G, Goerz G, Ruzicka T, Krutmann J. Green light is effective and less painful than red light in photodynamic therapy of facial solar keratoses. *Photodermatol Photoimmunol Photomed* 1997; 13: 181–185.
  23. Morton CA, Whitehurst C, Moore JV, MacKie RM. Comparison of red and green light in the treatment of Bowen's disease by photodynamic therapy. *Br J Dermatol* 2000; 143: 767–772.
  24. Fusco BM, Giacobozzo M. Peppers and pain. The promise of capsaicin. *Drugs* 1997; 53: 909–914.
  25. Bernstein JE, Korman NJ, Bickers DR, Dahl MV, Millikan LE. Topical capsaicin treatment of chronic postherpetic neuralgia. *J Am Acad Dermatol* 1989; 21: 265–270.
  26. Buck SH, Burks TF. The neuropharmacology of capsaicin: review of some recent observations. *Pharmacol Rev* 1986; 38: 179–226.
  27. Rains C, Bryson HM. Topical capsaicin. A review of its pharmacological properties and therapeutic potential in post-herpetic neuralgia, diabetic neuropathy and osteoarthritis. *Drugs Aging* 1995; 7: 317–328.
  28. Wiegell SR, Stender IM, Na R, Wulf HC. Pain associated with photodynamic therapy using 5-aminolevulinic acid or 5-aminolevulinic acid methylester on tape-stripped normal skin. *Arch Dermatol* 2003; 139: 1173–1177.
  29. Pagliaro J, Elliott T, Bulsara M, King C, Vinciullo C. Cold air analgesia in photodynamic therapy of basal cell carcinomas and Bowen's disease: an effective addition to treatment: a pilot study. *Dermatologic Surgery* 2004; 30: 63–66.
  30. Curnow A, Haller JC, Bown SG. Oxygen monitoring during 5-aminolaevulinic acid induced photodynamic therapy in normal rat colon – comparison of continuous and fractionated light regimes. *J Photochem Photobiol B – Biol* 2000; 58: 149–155.
  31. Muller S, Walt H, Dobler-Girdziunaite D, Fiedler D, Haller U. Enhanced photodynamic effects using fractionated laser light. *J Photochem Photobiol B* 1998; 42: 67–70.